



PROTOCOL **Efficacy of probiotics in the treatment of acute infectious diarrhoeal disease in African children: A protocol for systematic review and meta-analysis**
Alao Michael A, Adebayo Bosedede E, Oladokun Regina E, Ademola Adebowale D, Ogunbosi Babatunde O, Akindolire Abimbola A, et al

ORIGINAL RESEARCH **Dysglycaemia and Clinical Outcomes in Under-Five Children with Severe Acute Malnutrition at the Federal Teaching Hospital, Birnin Kebbi**
Falaye Monsurat A, Tahir Ali A, Abubakar Mansur, Lawal Teslim

Prevalence and Clinical Effects of Inappropriate Antidiuresis Syndrome in Children Hospitalised for Pneumonia at a Tertiary Health Facility in Nigeria
Hamzah Abdullateef, Ibraheem Rasheedat M, Katibi Oludolapo S, Ibrahim Tajudeen L, Sanusi Ibraheem, Aliu Rasaki

Spectrum of Paediatric Cardiac Diseases in a private echocardiography facility in Makurdi, North Central, Nigeria
Abah Rose O, Ochoga Martha O, Abdallah Ramatu J

Pediatric Vision Screening: School-Based Approach to Identify Childhood Eye Disease and Visual Impairment.
Adejumo Olubusayo O, Adeoti Caroline O, Olomola Bolanle V, Ubah Josephine N, Hassan Mustapha B, Olaopa Adedolapo O, et al

Microbiological profile, Antibiotic Susceptibility Pattern of Isolates and Outcome of Paediatric Parapneumonic Effusion in a Tertiary Facility, North-Western Nigeria
Abubakar Fatima I, Mohammed Yahaya, Ukwuani Solomon, Ahmed Hadiza K, Mikailu Abubakar J, Idrees Rufai A

Trends in Childhood Deaths in Lagos, Nigeria: An Autopsy Study
Soyemi Sunday S, Onayemi Oluwaseye O, Oluwatunbi Joy O, Mgbehoma Alban I, Sanni Daniel A, Oyewole Olugbenga O, Faduyile Francis A, Obafunwa John O

Orofacial Burkitt's Lymphoma: A 15-Year (2007-2021) Retrospective Review in a Nigerian Tertiary Hospital
Adefehinti Olufemi, Agboola Oluwatimilehin J, Fatusi Olawunmi A

CASE REPORT **Post Lightning-Strike Psychogenic Non-Epileptic Seizure: A Case Report**
Okafor Amarachukwu F, Ekekwe Nkechi, Enwereji Ngozi U, Chukwudi Ndubisi K, Ukpabi Ihuoma K

Retained Plastibell Device Following Neonatal Circumcision: A Case Report and Literature Review
Chisor-Wabali, Egbuchilem, Ijah Rex FOA

Unusual Presentation of Ewing sarcoma in a Black Adolescent: A Case Report and Literature Review
Urom Kelechi O, Chukwu Bartholomew F, Olusina Daniel B, Iloanusi Nneka I, Onuh Augustine C, Okezie Juliet G, et al.



Nigerian Journal of Paediatrics 2025; Volume 52(4):403-408.

<https://dx.doi.org/10.63270/njp.v52i4.2000042>.

Retained Plastibell Device Following Neonatal Circumcision: A Case Report and Literature Review

Chisor-Wabali Egbuchilem, Ijah Rex FOA

Department of Surgery, Rivers State University Teaching Hospital (RSUTH), Port Harcourt, Nigeria.

Correspondence

Dr Chisor-Wabali Egbuchilem. Department of Surgery, Rivers State University Teaching Hospital (RSUTH), Port-Harcourt, Rivers State, Nigeria. E-mail: chisor-wabali.egbuchilem@rsu.edu.ng ;

ORCID – <https://orcid.org/0000-0002-2141-6537>.

Abstract

The Plastibell device is a known appliance/method for neonatal circumcision. The objective of the report is to describe one of the complications of neonatal circumcision using “Plastibell device” and to create awareness about this complication of a widely used surgical procedure. A 23-day-old male presented with swelling at the circumcision area of about five days. There was associated excessive crying while bathing or cleaning the area. The baby was circumcised 16 days earlier, by a nurse at a primary health centre and the object used for the circumcision – the Plastibell device was yet to fall off. The penis was oedematous and harboured a transparent cylindrical plastic object (Plastibell device). The distal third of the penis was depressed, and the glans penis was oedematous, but not cyanosed or gangrenous. There was no associated ulceration or discharge, and the patient was able to pass urine. The device was manually removed following lubrication. There was normal urinary function post-removal, and no associated complications on follow-up. In conclusion, retained Plastibell device is a complication of circumcision, and adequate parental counselling is vital. There is a need for re-education of health workers and upscaling of regulatory actions by governmental agencies and healthcare practitioners regarding its use of the Plastibell device.

Keywords: *Circumcision, Foreskin, Parental anxiety, Phallus.*

Introduction

Plastibell device is a transparent “ring-on-spoon” plastic detachable device marketed by Hollister Inc. USA, and it is used in the controlled removal of the foreskin from the glans of the penis in the procedure of circumcision. Circumcision reportedly started in Ancient Egypt,^{1,2} although it was not clearly stated whether it was for hygiene, religious, or cultural reasons. However, it is a common practice among the Jews, Christians, and Muslims.³ Neonatal circumcision of the male child is a very common surgical procedure performed globally,^{4,5} and 37–39% of all men globally are known to be circumcised, as

reported in 2016.⁶ However, while a large pool of individuals patients are circumcised in some countries,^{6,7} others report low uptake of circumcision among their patients.^{8,9} There are many methods of carrying out this procedure, and one of such methods is the use of the Plastibell device.

Circumcision, just like other surgical procedures, may be associated with some complications.^{10,11} In a multicenter study, a complication rate of 1.1% was reported out of 2,276 male circumcisions carried out with the Plastibell device, and the average device fall-off time was 6 days with a range of 4-12 days.⁷ One possible

complications following the use of the device is retained Plastibell – a condition in which the ring of the device fails to fall off.

Critical in contributing to the retained Plastibell device are improper sizing (a device that is too small), delayed tissue necrosis (when the ligature of the foreskin on the plastic device is loose), or migration of the ring. Additionally, the Plastibell device tied with polypropylene size “0” has been reported to fall off relatively faster than that tied with cotton threads.¹² A 10-year study from two countries - Saudi Arabia and Egypt – reported some cases of Plastibell retention among the complications of circumcision.¹³ There were other studies outside Africa highlighting the same.¹⁴⁻¹⁷ In Africa, a multicentre study observed 11 cases of retained Plastibell devices (0.48%) out of 2,276 male infants who had Plastibell circumcision.⁷ It is important to state here that in this study, resident doctors and medical officers were in charge of the procedures. Another multicentre regional study observed 28 cases (19.6%) of retained Plastibell out of the 143 circumcision-related complications reported over a 7-year study period.¹⁸ Patients who were referred from other peripheral centres following complications of circumcision were included in this report.

Despite the benefits of the Plastibell device in circumcision, necessitating its global adoption in reducing complications, some challenges still exist. Some undesirable outcomes may be inescapable following surgery (examples include post-operative pain and surgical site infection), but retention of the Plastibell device is avoidable, and hence does not seem to be inescapable. In a study conducted across three tertiary hospitals in south-eastern and southern Nigeria, and reported in 2018, some cases of retained Plastibell were described. In this study, only about half of the total number of circumcisions seen were carried out by medical doctors and nurses, while the rest

were performed by semi-skilled or unskilled healthcare staff.¹⁸ Many years after that report, retained Plastibell still occurs, and circumcision by unskilled personnel is still happening. The literature is also scanty on the occurrence of this complication of circumcision in Port Harcourt City, Nigeria, hence this report. This study aimed to report and review the literature for a case of retained “Plastibell device” following neonatal circumcision.

Case Presentation

A 23-day-old male presented at the Children’s Emergency Ward (CHEW) of the Rivers State University Teaching Hospital, Port Harcourt, Nigeria, with a complaint of swelling in the area of circumcision of five days duration. There was associated excessive crying while bathing or cleaning the area. The baby had a circumcision done on the seventh day of birth (16 days earlier), by a nurse at a primary health centre and the object used for the circumcision – the Plastibell device was yet to fall off. Although the parents were informed that the object would fall off, they were still hoping for that to happen until they observed the above complaints. With no given date for a follow-up visit, the anxiety was confirmed by a medical doctor who came on a visit and they were advised to seek urgent medical attention. The parents both had tertiary levels of education, and were a newly married couple nursing their first male child. There is no other significant information in the history.

The general condition of the baby was normal (except when touching the area of pathology). The respiratory, cardiovascular, and musculoskeletal systems examination revealed normal findings. There were normal findings in the abdomen. Significant findings were only present in the genitourinary system. There was an oedematous phallus, harbouring a transparent plastic cylindrical object (Plastibell device). The distal third of the penis was depressed, and the

Retained Plastibell Device Following Neonatal Circumcision: A Case Report and Literature Review

glans penis was edematous, but not cyanosed or gangrenous. There was no associated ulceration or discharge, and the patient was able to pass urine.

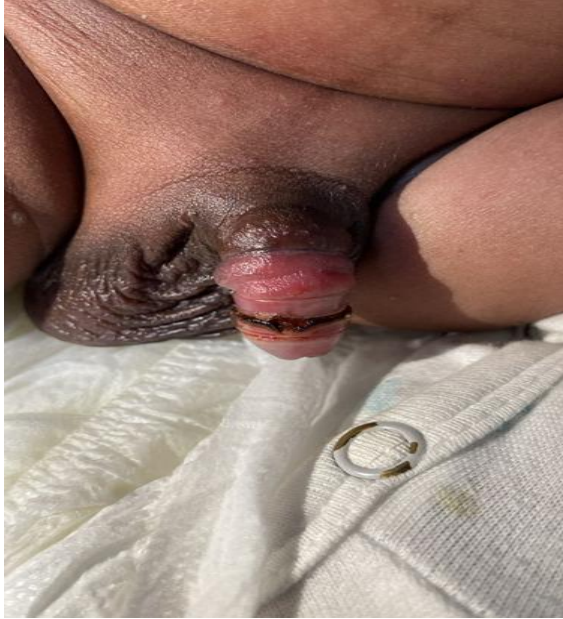

Figure 1: Retained Plastibell device at presentation (before removal)

A diagnosis of a retained Plastibell device following neonatal circumcision was made. Gentle manual rotation of the Plastibell ring was performed after lubrication, allowing gradual dislodgment without the need for surgical instruments or anaesthesia. The ring detached completely, and thereafter the baby received antibiotics and analgesics. The oedema resolved within 48 hours. There was normal urinary function post-removal, and no adhesions or granulomas developed during follow-up. The parents gave permission for the use of the baby's images and other data in this research.

Discussion

The index case is a male neonate who presented on the 23rd day of life 16 days after a Plastibell circumcision was done. This implies a retention of the device because it was still attached beyond the period it was expected to fall off, as reported

earlier.⁷ There was considerable parental anxiety at presentation. Similar parental and health workers' anxiety was reported in previous studies.¹² Health education (during the antenatal period, before and after circumcision) has been reported to improve knowledge and reduce parental anxiety associated with such events.¹⁹

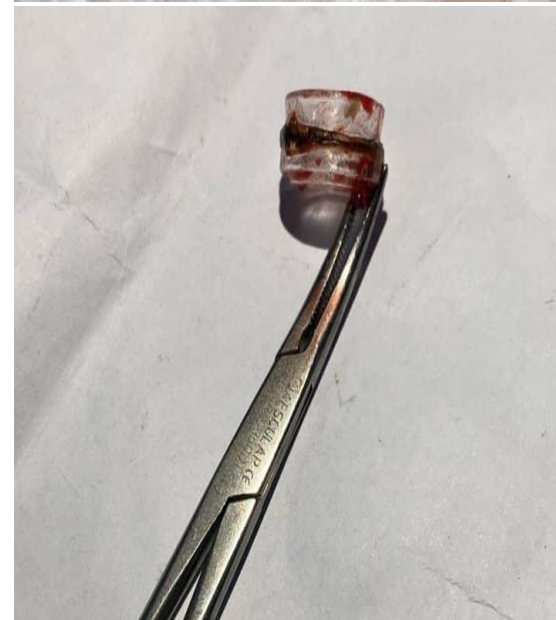
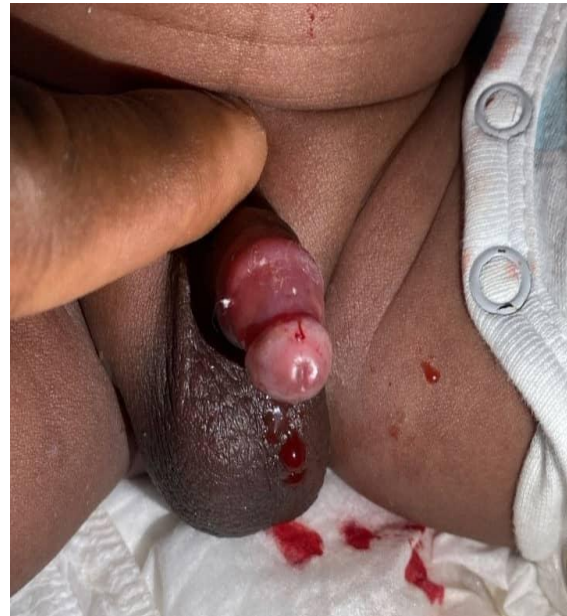

Figure 2: The penis and the Plastibell device after removal of the retained device

The parents were a newly married couple, nursing their first male child, which suggests some level of inexperience in the care of the child after circumcision. This may have contributed to the delay in recognition and presentation at the hospital. The high level of education in both parents may translate to better understanding and better compliance with health instructions, regarding the care of their newborn child. Therefore, the plausible explanation for the occurrence of the clinical condition is likely to be a healthcare personnel factor, which may have been inadequate counselling before and after the circumcision and procedure/technical issues. This line of thought is strengthened by the fact that the procedure was carried out by a semi-skilled personnel. A Plastibell device retention rate of 0.48% was earlier reported in a study where the procedure was carried out by trained doctors (residents and medical officers),⁷ compared with a rate of 19.6% in another study where the procedure was done by both skilled and untrained staff.¹⁸ In addition to skill, appropriateness of Plastibell size is equally important in the risk of retention. Choosing the right size prevents retained Plastibell and other complications as reported by Nasir *et al.*²⁰ where the choice of Plastibell size derived via a formula gave better outcomes compared to visual estimation. The latter technique is commonly used but it requires experience which was lacking in the index case. In the report by Nasir *et al.*²⁰ there no complications in the cohort whose Plastibell size were formula derived.

Management strategies for the removal of retained Plastibell include manual removal, use of ring cutters, and surgical excision for embedded or complicated cases. Early recognition and intervention are critical to prevent further complications. In the index case, gentle manual, well-lubricated rotation was used, and the outcome was satisfactory. This approach is appropriate when there is no significant

oedema, infection, or tissue embedding. It is minimally invasive and avoids the need for anaesthesia or specialized equipment. The manual method was successful in the index case because the penile oedema was not severe. However, for cases with significant swelling, migration, or tissue embedding, ring cutters or surgical intervention may be necessary.^{21,22} A report had highlighted the use of a ring cutter after failure of the manual method in a case of significant edema.¹⁶

Limitations

This is a case report, a single incident with potential for other unreported occurrences. Our report, therefore, opens the opportunity for a multicentre study in Port Harcourt, which could more succinctly document the scope of occurrence of Plastibell device retention and therefore, provide stronger evidence for advocacy.

Conclusion

This report highlights one of the complications of neonatal circumcision using the Plastibell device. A retained Plastibell device is an avoidable complication of circumcision, and early recognition and intervention are essential. Manual rotation is an effective first-line approach in the absence of penile oedema. It is recommended that training and re-training of health workers on proper usage of the Plastibell device should be emphasised, especially at the primary healthcare level. Parental education on the expected time frame for ring detachment and warning signs of complications is also essential. Regulatory agencies and professional organizations should upscale the monitoring of practitioners to forestall and reduce unskilled surgical interventions in circumcision.

Acknowledgement: The authors acknowledge the parents of the patient and the Research Ethics Committee of the Hospital for the kind permission granted for the publication of this case report.

Authors' Contributions: Both authors conceived the research, drafted the manuscript, revised the draft for sound intellectual content and approved the final version of the manuscript.

Conflicts of Interest: None declared.

Funding Supports: The authors did not receive any financial support for this research or for the preparation of this manuscript.

Accepted for publication: 27th October 2025.

References

1. Totaro A, Volpe A, Racioppi M, Pinto F, Sacco E, Bassi PF. Circumcision: history, religion and law. *Urologia J.* 2011;78(1):1-9.
2. Militello C, Pais V. Male circumcision: History of current surgical practice. *Circumcision-Advances and New Perspectives: IntechOpen;* 2023.
3. Shinde ND, Moinuddin M, Danish A. Plastibell circumcision in neonates and infants at tertiary care centre. *Int Surg J.* 2018;5:1488-91.
4. Simpson E, Carstensen J, Murphy P. Neonatal circumcision: new recommendations & implications for practice. *Missouri Med.* 2014;111(3):222.
5. Circumcision TFO, Blank S, Brady M, Buerk E, Carlo W, Diekema D, *et al.* Male circumcision. *Pediatrics.* 2012;130(3):e756-e85.
6. Morris BJ, Wamai RG, Henebeng EB, Tobian AA, Klausner JD, Banerjee J, *et al.* Estimation of country-specific and global prevalence of male circumcision. *Pop Healthmetrics.* 2016;14:1-13.
7. Jimoh BM, Odunayo IS, Chinwe I, Akinfolarin OO, Oluwafemi A, Oluosanmi EJ. Plastibell circumcision of 2,276 male infants: a multi-centre study. *Pan Afr Med J.* 2016;23(1).
8. Ntsabane M, Letamo G, Keetile M. Factors associated with low uptake of safe male circumcision (SMC) and the intention not to undergo circumcision among men in Botswana. *J Public Health.* 2025;33(2):445-55.
9. Drain PK, Halperin DT, Hughes JP, Klausner JD, Bailey RC. Male circumcision, religion, and infectious diseases: an ecologic analysis of 118 developing countries. *BMC Infect Dis.* 2006;6:1-10.
10. Iacob SI, Feinn RS, Sardi L. Systematic review of complications arising from male circumcision. *BJUI Compass.* 2022;3(2):99-123.
11. Merga TG, Ahmed MM, Zeray R, Amsalu R, Girma H. Post circumcision dorsal urethrocutaneous fistula in pediatric male patient: A case report and literature review. *Int J Surg Case Reports.* 2024;124:110307.
12. Altokhais T, Elsarrag A, Khan S, Alshehri A, Albassam A. Neonatal Plastibell circumcision: does the thread type matter? a prospective randomized study. *J Pediatr Urol.* 2019;15(5):562.e1-e5.
13. Hamed A, Helal AAE, Badway R, Goda SH, Yehya A, Abd Razik M, *et al.* Ten years experience with a novel modification of Plastibell circumcision. *Afr J Paediatr Surg.* 2014;11(2):179-83.
14. Netto JMB, Araujo Jr JGD, Noronha MFDA, Passos BR, Lopes HE, Bessa Jr JD, *et al.* A prospective evaluation of Plastibell® circumcision in older children. *Int Braz J Urol.* 2013;39(4):558-64.
15. Muneeb MD, Baig MAN. Proper Technique Prevents Poor Performance And Fate: A Comparison Of Circumcision By Plastibell Method In Neonates And Infants. *J Dow University Health Sci.* 2019;13(1):37-42.
16. Fanny SA, Chumpitazi CE. Infant with swollen penis and apparent dysuria. *Clin Exp Emerg Med.* 2020;7(2):136.
17. Smith A, Hebra A, Mansfield J, Streck C. Management of Plastibell circumcision ring migration and glans penis incarceration. *J Pediatr Surg Case Reports.* 2013;1(7):186-8.
18. Okoro PE, Ekeke NO. Severity of malcircumcisions and circumcision-related complications in three tertiary health facilities in Southern Nigeria. *Ann Pediatr Surg.* 2018;14(3):130-3.

19. Chang S-F, Hung C-H, Hsu Y-Y, Liu Y, Wang T-N. The effectiveness of health education on maternal anxiety, circumcision knowledge, and nursing hours: a quasi-experimental study. *J Nurs Res.* 2017;25(4):296-303.
20. Nasir AA, Bamigbola KT, Abdur-Rahman LO, Adeniran JO. Choosing an appropriate Plastibell size for infant circumcision. *J Clin Sci.* 2018;15(3):123-5.
21. Bode C, Ikhisemojie S, Ademuyiwa A. Penile injuries from proximal migration of the Plastibell circumcision ring. *J Pediatr Urol.* 2010;6(1):23-7.
22. Jayaratne N, Zaghal A, Weir J, Choudhry M. A Case of foreign body granuloma after Plastibell [R] circumcision. *Pediatr Urol Case Reports.* 2018;5(1):16-22.