

**Aigbe IC**  
**Omo-Okhuasuyi G**  
**Olufemi P**  
**Okugbo SU**  
**Nwaneri DU**  
**Osarogiagbon WO**  
**Sadoh AE**

CC –BY **Disk battery ingestion mimicking acute tonsillitis in a Nigerian child: A case report**

DOI:<http://dx.doi.org/10.4314/njp.v46i3.6>

Accepted: 17th September 2019

Sadoh AE (✉)  
 Aigbe IC, Omo-Okhuasuyi G  
 Nwaneri DU, Osarogiagbon WO  
 Department of Child Health,  
 University of Benin Teaching  
 hospital, Benin City, Edo State,  
 Nigeria.  
 Email: [evawere.sadoh@uniben.edu](mailto:evawere.sadoh@uniben.edu)

Olufemi P, Okugbo SU  
 Cardiothoracic Unit  
 University of Benin Teaching  
 hospital, Benin City, Edo State,  
 Nigeria.

**Abstract:** There is a rising incidence of disk battery ingestion in children. This is due to their increased use in electronic devices (including toys) commonly found in the home setting. Children below the age of 6 years are mostly affected with peak incidence in the ages of 1 to 3 years. Although most disk batteries when ingested pass through the gastro intestinal tract harmlessly, they may be lodged in the oesophagus causing significant destructive injury within 4-6 hours of impaction due to their corrosive nature. Impaction of foreign bodies may present with specific symptoms, non specific symptoms or may be asymptomatic. We present an 11 month old child in whom an ingested disc battery had been lodged in the oesophagus for 6 days prior to retrieval by rigid endoscopy. The presence of a clinical history and

examination findings supporting a diagnosis of acute tonsillitis was misleading, causing regrettable delays in the diagnosis and management of this child, who subsequently developed a tracheoesophageal fistula.

A high index of suspicion by clinicians is needed especially in the non verbal child for early identification and to prevent complications. Increased awareness by parents and other care givers of the hidden dangers of these innocuous-looking batteries in homes and legislation directing the need for child safety locks on disk battery compartments of electronic gadgets and toys will help in reducing the incidence of battery ingestion cases in children.

**Key words:** Disk, battery, ingestion, mimic, Acute tonsillitis

## Introduction

Foreign body ingestion is common in children and occurs mostly between the ages of 6months to 3 years.<sup>1,2</sup> Worldwide, coins are the most commonly ingested foreign bodies.<sup>1</sup> But with technological advancement, there has been an increase in the use of disk batteries to power children's toys, watches, calculators and remote control gadgets, with children accidentally ingesting disk batteries.<sup>1,2</sup> These batteries may easily be removed from the gadgets and considering the propensity of children below the age of 4 years to put objects indiscriminately in their mouths, their incomplete dentition and immature swallowing coordination, these objects are easily swallowed.<sup>1,4</sup> If ingestion occurs in a child yet to attain speech and in the absence of a witness to report the incident, this may pose a diagnostic challenge to an unsuspecting clinician due to varying clinical presentations. Most foreign bodies in the oesophagus move down the gastrointestinal tract and are passed out unhindered via the anus.<sup>2,5</sup> But for those trapped in the esophagus, they

may likely lodge at one of three areas of esophageal narrowing: the upper oesophageal sphincter (cricopharyngeus), the aortic arch and the level of the lower oesophageal sphincter. The oesophageal impaction of a disk battery is considered a surgical emergency due to its rapidly corrosive nature (it can cause mucosal injury in as little as 1 hour of contact time) and must be expeditiously removed.<sup>2,5,6</sup> Oesophageal perforation and tracheoesophageal fistula are common complications following long term impaction of disc battery ingestion.<sup>2,5</sup>

Following oesophageal impaction of a foreign body, 30% of children may be asymptomatic.<sup>1,2,5</sup> The child may present with an initial bout of choking, gagging and coughing which may be followed by excessive salivation, dysphagia, refusal of feeds, vomiting, pain in the neck, throat or sternal notch regions. Respiratory symptoms such as stridor, wheezing, cyanosis or dyspnea may be encountered if the foreign body impinges on the larynx or the membranous posterior tracheal wall.

Cervical swelling, erythema or crepitations point to perforation of the oropharynx or proximal oesophagus. Diagnosis have been initially missed by health providers in about half of fatal cases due to no initial history of ingestion and nonspecific presenting symptoms such as vomiting, fever, lethargy, poor appetite, irritability, wheezing, cough, and/or dehydration.<sup>1,2</sup>

Acute tonsillitis is inflammation of the pharyngeal tonsils. It is a common infection in children, mostly between the ages of 3 to 7 years.<sup>7</sup> Viruses are mostly implicated as the cause but Group A Beta-haemolytic streptococcus (GABHS) is the commonest bacterial cause. Symptoms include fever, vomiting, sore throat, drooling of saliva, dysphagia, odynophagia, foul breath and poor appetite. These symptoms are similar to some of those that may be present in foreign body ingestion.<sup>7</sup> Signs may include dry tongue, erythematous enlarged tonsils, tonsillar or pharyngeal exudates, palatine petechiae and tender cervical lymph nodes. Airway obstruction may manifest as mouth breathing, snoring, sleep disordered breathing and sleep apnea.<sup>7</sup>

Tonsillitis is a clinical diagnosis. Throat cultures are done to detect bacterial causes. Viral cultures are often unavailable and are generally too expensive and slow to be clinically useful.

Treatment of acute tonsillitis is largely supportive and focuses on ensuring adequate hydration and caloric intake, also, controlling pain and fever. GABHS or other bacterial infection requires antibiotic treatment.

A plain anteroposterior radiograph of the neck, chest and abdomen, along with lateral views of the neck and chest are paramount in evaluating a child with a history of foreign body ingestion. The flat surface of a disc battery in the oesophagus is seen on the anteroposterior view and the edge on the lateral view.<sup>1,2</sup>

Treatment of oesophageal foreign body is by rigid oesophagoscopy and removal of the foreign body, with an endotracheal tube protecting the airway.<sup>1,2,5</sup>

In this article, we present a case of disc battery ingestion in an 11 month old infant who presented with features of acute tonsillitis.

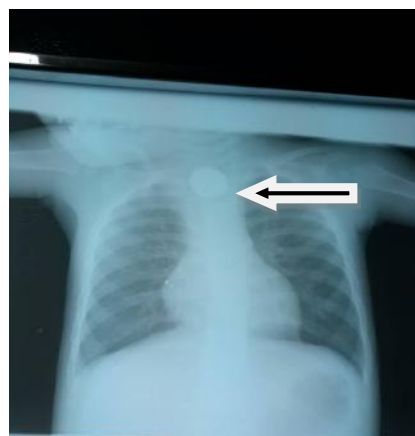
### Case Report

A.E, an 11 month old male (2nd of a set of twins) presented at the Outpatient Clinic of University of Benin Teaching Hospital, Benin city, Edo State with a three day history of sudden onset of persistent vomiting while at play, refusal to feed, fever and a two day history of cough, intermittent noisy breathing and restlessness. He had no previous history of admission. The twins are the only children in a monogamous setting and the index patient was under the supervision of a 10 year old relative when the symptoms started. Mother is a 35 year old stay-at-home mum with secondary level of education and his father, a 47 year old spare parts dealer with secondary level of education. The socioeconomic class of the family as determined using the method described by Oyedeji<sup>8</sup> was III.

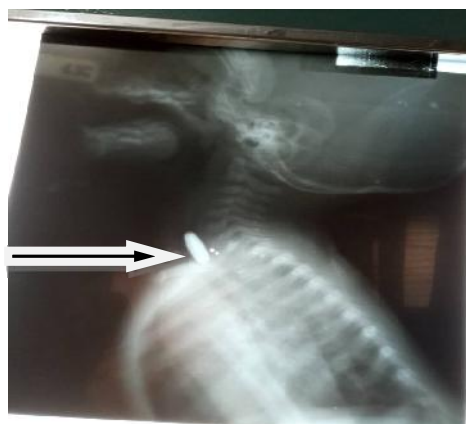
On examination, he was acutely ill looking with a low

grade fever (37.8°C). He weighed 10kg (100% of expected for age and sex). His tonsils were enlarged (grade III) and hyperaemic, with absence of exudates. There was no excessive salivation. He was not dyspnoeic but had a respiratory rate of 62 cycles per minute. His breath sounds were vesicular and had widespread transmitted sounds. All other systems were normal. A diagnosis of acute tonsillitis was made and he was placed on suspension cefuroxime and syrup ibuprofen on an outpatient basis. However, two days later, he was brought to the children's emergency room with persistence of the vomiting, fever, refusal of feeds and worsening of the cough (although the noisy breathing had ceased). On examination, he was acutely ill looking, febrile (38.4°C), not pale, not dehydrated and saturating at 96% in room air. He was tachypnoeic (respiratory rate 68 cycles per minute), not dyspnoeic with vesicular breath sounds. All other systems were normal. He was then admitted with a diagnosis of Acute tonsillitis with persistent vomiting and commenced on intravenous cefuroxime and gentamicin, and also placed on intravenous fluids. However, after two days on admission, he had become pale, lethargic and dyspnoeic with wide spread coarse crepitations. Oxygen saturation remained 96% in room air. Chest radiography (anteroposterior and lateral views) done at this point revealed a roundish opaque material in the distal cervical oesophagus compressing the trachea. (Figures 1 and 2)

**Fig 1:** A plain radiograph (AP view) of the neck and chest showing a roundish opaque object in the oesophagus.



**Fig 2:** A Plain radiograph of the lateral soft tissue of the neck.



His packed cell volume was 19% for which he received blood transfusion (sedimented red blood cells). He also had hypokalemia (2.5mmol/L) which was corrected. He was subsequently intubated and rigid oesophagoscopy was performed to remove the foreign body. Surgical findings revealed inflamed and friable oesophageal mucosa at the level of the thoracic inlet about 20cm from the incisors.

Examination of the foreign body revealed a disk battery of 25mm in diameter with signs of corrosion (Figures 3 and 4). Post operatively, intravenous ceftriaxone and metronidazole were administered. Nil per os was maintained

**Fig 3 and 4.** Anterior and posterior surfaces of the corroded disk battery retrieved.



Four hours post op, he developed stridulous breathing with drooling of saliva. A three day course of intramuscular dexamethasone at 0.15mg/kg/dose 8hourly was administered. Symptoms resolved within 24 hours. Nasogastric tube feeding was commenced four days post operatively and this was well tolerated.

However, seven days post operation, a trial of oral water intake elicited a bout of severe coughing and vomiting. He developed respiratory distress with wide spread coarse crepitations a few minutes after the trial. A tracheo-oesophageal fistula with aspiration was suspected. However, a barium swallow contrast study done revealed no stricture or defect suggestive of a tracheo-oesophageal fistula or oesophageal perforation. Oral feeds were recommenced by the fifth week post-operation. Due to the persistent cough, fever, and worsening of difficulty with breathing, barium swallow contrast study was repeated and it showed a tracheo-oesophageal fistula. Nil per Os was recommenced and a gastrostomy tube for feeding was placed. The child is presently being worked up for definitive management.

## Discussion

The incidence of disk battery ingestion in the paediatric age group is on the rise, due to its use by the growing number of portable electronic devices. This has been noted by various researchers.<sup>1-3</sup> Prior to 1983, there were

6 reported cases of disk battery ingestion in the United States of America<sup>1</sup>. But from 1985-2009, 56,535 disk battery ingestions were reported to the United States National Poison Data System<sup>1</sup> and 13 (0.02%) of these cases were fatal.<sup>1</sup> Although there is no National registry for cases of battery ingestion in Nigerian children, cases of disk battery ingestion have been reported from Nigeria.<sup>9</sup>

The case presented is an 11 month old child, which is in keeping with previous reports in which the usual age group in which ingestion commonly occurs is 6months to 5 years.<sup>1-3,9</sup>

Being a male toddler also agrees with the findings of Okhaku et al<sup>10</sup> in 2013 that male children are more affected than females. This is probably due to the more active and exploratory nature of boys in comparison to their female counterparts, making them more prone to foreign body ingestion. Inadequate child supervision has also been linked to unintentional injuries including foreign body ingestion.<sup>11</sup> Some studies have shown that supervision of young children by older children as shown in the case presented is associated with an increased risk of unintentional injury.<sup>11,12</sup> Researches worldwide have consistently shown that children from low socioeconomic class are associated with a higher incidence of childhood accidental injuries and morbidities.<sup>13,14</sup> However, in the case presented this may not have played a role as the child was from a middle socioeconomic class.

The size of ingested foreign bodies can determine the likelihood of impaction. An ingested disk battery of 20mm and above in diameter is associated with a high risk of oesophageal impaction.<sup>1,2,8</sup> The battery ingested by our patient was 25mm in size.

The thoracic inlet has been reported to be the narrowest point and the most common site of foreign body impaction, as was the case in the patient presented.<sup>1,2,9</sup>

Unwitnessed cases in non-verbal children can easily be mis-diagnosed causing delays as was the case in the patient presented.<sup>1,2</sup> The non specific symptoms of vomiting, fever and refusal of feeds also contributed to the delay in diagnosis. These symptoms can be present in many common childhood illnesses such as malaria and acute tonsillitis. The presence of inflamed tonsils further lent credence to the diagnosis of acute tonsillitis further reducing the index of suspicion for a foreign body. Disk battery ingestion being missed due to a diagnosis of acute tonsillitis has previously been reported.<sup>15</sup> It is possible that the lesion in the tonsils may have been due to the recurrent vomiting<sup>16</sup> or possibly the presence of the battery irritating the pharynx.

A delay in diagnosis may lead to prolonged lodgement of the battery in the oesophagus, thereby increasing the risk of complications associated with disk battery ingestion ranging from minor oesophageal burns, which can lead to oesophageal strictures to trachea-oesophageal fistula, and even aorto-oesophageal fistula.<sup>9,17,18</sup> Following removal of the disk battery, his parents on hindsight recalled that he often played with a remote

control, powered by a lithium disk battery which had become missing from its battery compartment in the remote, prior to the onset of their child's symptoms. The battery compartment had an extremely poor child tamper proof measure (clip lock) which is an important risk factor with battery ingestion in children.<sup>1</sup>

The use of plain radiograph in determining the location and the type of foreign body in the digestive tract proved invaluable in making an accurate diagnosis in this case. The findings of other researchers have attested to this.<sup>1-4</sup> In the retrieval of an oesophageal foreign body, the procedure commonly employed is the use of rigid oesophagoscopy, which was used in the removal of the foreign body in this patient.<sup>1-4</sup> Oesophagoscopy may be associated with iatrogenic dental injury, laryngeal injury with voice change, oesophageal perforation with bleeding, aortic rupture which may lead to aorto-oesophageal fistula.<sup>19-21</sup> Oesophageal perforation may cause mediastinitis and fulminant sepsis, which may lead to death.<sup>19-21</sup>

The patient unfortunately developed a tracheo-oesophageal fistula, a common complication with prolonged lodgement of an ingested disc battery.<sup>9,17,18</sup>

---

## Conclusion

With the widespread use of disc batteries and its easy availability in homes, they no doubt pose a source of

immense danger to children in our modern day setting. Preventing battery ingestion and limiting the dangers inherent in their ingestion can be achieved by multiple interventions. An important intervention is ensuring that children do not have access to them. In homes, parents and caregivers must be educated on the dangers disk batteries pose to children and must keep them far out of their reach and disposed off safely. Children's playtime should always be supervised by a grown up. Once ingestion of a disk battery has occurred or is suspected, caregivers must ensure that the child is taken to the emergency room immediately.

Clinicians must have a high index of suspicion, be able to make a prompt diagnosis and ensure quick retrieval of the battery to prevent the devastating complications from the corrosive agents in the battery. Clinicians should also consider possible foreign body ingestion in non verbal children whose response to standard management of acute tonsillitis is suboptimal. The government can play a major role in preventing the potential hazards of battery ingestion by ensuring that manufacturers make packaging of new batteries more secure and all battery packs to be labelled boldly with the warning "keep away from children". Also, the government can ensure that manufacturers of electrical devices make their disk battery compartments child proof by requiring a tool to open the compartment. A National registry for cases of foreign body ingestion should also be encouraged to formulate better management strategies and thus reduce morbidity.

---

## References

- Litovitz T, Whitaker N, Clark L, White NC, Marsolek M. Emerging battery-ingestion hazard: clinical implications. *Pediatrics* 2010; 125:1168-77.
- Okpala NC. Disc batteries impaction in the oesophagus. *J Sc Tech* 2008; 28: 1-3.
- Anil K.L. Current Diagnosis and Treatment in Otolaryngology- Head and Neck Surgery. 3rd Ed. McGraw hill companies, 2011; New York. Pages 543-54.
- Ibekwe MU, Onotai LO, Otaigbe B. Foreign bodies in the Ear, Nose and Throat in children: a five year review in Niger Delta. *Afr J Paediatr Surg*, 2012; 9: 3-7.
- Marom T, Goldfarb A, Russo E, Roth Y. Battery ingestion in children. *Int J Pediatr Otorhinolaryngol.* 2010; 74:849-54.
- Onotai LO, Ibekwe MU, George I. Impacted Foreign Bodies in the Larynx of Nigerian Children. *J Med Sci* 2012; 217-26.
- Stelter K. Tonsillitis and sore throat in children. *GMS Curr Top Otorhinolaryngol Head Neck Surg.* 2014; 13:Doc07. Published 2014 Dec 1. doi:10.3205/cto0001107.
- Oyedemi GA. Socio-economic and cultural background of hospitalized children in Ilesa. *Niger J Paediatr* 1985;12:111-7.
- Umana A, Offiong M, Mgbe R, Etiuma A, Adekanye A, Ewa A, Ette V. Disk battery foreign bodies in children and major outcomes in the southern part of South Nigeria. *The Int J Oto* 2012; 14:2.
- Okhakhu AL, Okolugbo NE, Onyeagwara NC. Disk battery in the nasal cavity: case series. *Int J Mod Alt Med Res* 2013; 5:5-8.
- Kavinda Chandimal Dayasiri MB, Jayamanne SF, Jayasinghe CY. Risk Factors for Acute Unintentional Poisoning among Children Aged 1-5 Years in the Rural Community of Sri Lanka. *Int J Ped* 2017. Available at <http://doi.org/10.1155/2017/437598> 7 Accessed 8th August 2019
- Ruiz-Casares M, Nazif-Muñoz JI, Iwo R, Oulhote Y. Nonadult Supervision of Children in Low- and Middle-Income Countries: Results from 61 National Population-Based Surveys. *Int J Environ Res Public Health*, 2018. 15:1564. doi:10.3390/ijerph15081564
- Birken CS, Macarthur C. Socioeconomic status and injury risk in children. *Paediatr Child Health*, 2004;9(5):323-325. doi:10.1093/pch/9.5.323

14. Laflamme L, Hasselberg M, Burrows S. 20 Years of Research on Socioeconomic Inequality and Children's—Unintentional Injuries Understanding the Cause-Specific Evidence at Hand. *Int J of Pediatr*. 2010, Article ID 819687, 23 pages <http://dx.doi.org/10.1155/2010/819687>
15. Sindi E, Bahadur A, AlRajhi H, Yousef Y. Disc battery ingestion; a single event with different outcomes. *Int J Ped Adol Med* 2017; 4: 87-90.
16. Bannister M. Tonsillitis caused by vomiting in a patient with Bulimia Nervosa: A case report and literature review. *Case Reports in Otolaryngology*. Volume 2013, Article ID 251629, 2 pages. Available at <http://dx.doi.org/10.1155/2013/251629>
17. Slamon NB, Hertzog JH, Penfil SH, Raphaely RC, Pizarro C, Derby CD. An unusual case of button battery-induced traumatic tracheoesophageal fistula. *Pediatr Emerg Care* 2008; 24: 313-6.
18. Khaleghnejad TA, Mirshemirani A, Rouzrokh M, Seyyedi J, Khaleghnejad TN, Razavi S, Talebian M. Tracheoesophageal fistula following disc battery ingestion and foreign body impaction. *Caspian J Intern Med* 2011. 2: 336-39.
19. Majeski J, Lynch W, Durst G. Esophageal perforation during esophagogastroduodenoscopy. *Am J Surg*. 2009; 198:56-57.
20. Bhatia NL, Collins JM, Nguyen CC, Jaroszewski DE, Vikram HR, Charles JC. Esophageal perforation as a complication of esophagogastroduodenoscopy. *J Hosp Med* 2008; 3: 256-62.
21. Onotai LO, Etawo US. The challenges of rigid oesophagoscopy in the management of oesophageal foreign bodies in Port Harcourt. *Int J Med med sci*.2012; 2: 108-13.